

Rapporteurs:

Noa Frank, David Domb, Nora Jaber, and Adi Schwartz,
supervised by Prof. Moshe Goldstein

Affiliation:

Postgraduate programme in periodontology, Hadassah Medical Center
and Hebrew University, Jerusalem, Israel

study

Reduced bone dimension in patients with oligodontia

Authors:

Nicolas Dupré, Benjamin P. J. Fournier, Orianne Gondel, Margot C. Riou, Juliane Isaac, Pascal Garrec, Brigitte Vi-Fane, Samia Kribel, Muriel De La Dure-Molla, Maria Clotilde Carra, Rufino Felizardo, Stephane P. Kerner

Background

Literature is scarce about the expected dimensions and healing of the edentulous alveolar bone in patients with oligodontia (OD). Interestingly, bone remodelling after tooth loss exhibits first resorption in the horizontal dimension followed by the vertical dimension.

Patients with oligodontia – defined as the lack of six teeth or more – need restorative solutions to achieve proper mastication. This anomaly is of genetic origin in most cases, and it can appear as a part of a syndrome or as a lone condition.

Many solutions include an implant-supported prosthesis, which is dependent on the alveolar bone available. Because of this limitation, placing dental implants in such locations may complicate the rehabilitation prosthesis.

For implant placement, the minimum width and height of the alveolar crest should be at least 6mm to avoid dehiscence and proximity to anatomical structures.

To date, no study published in this field has shown a quantitative analysis regarding bone height and width in these types of cases.

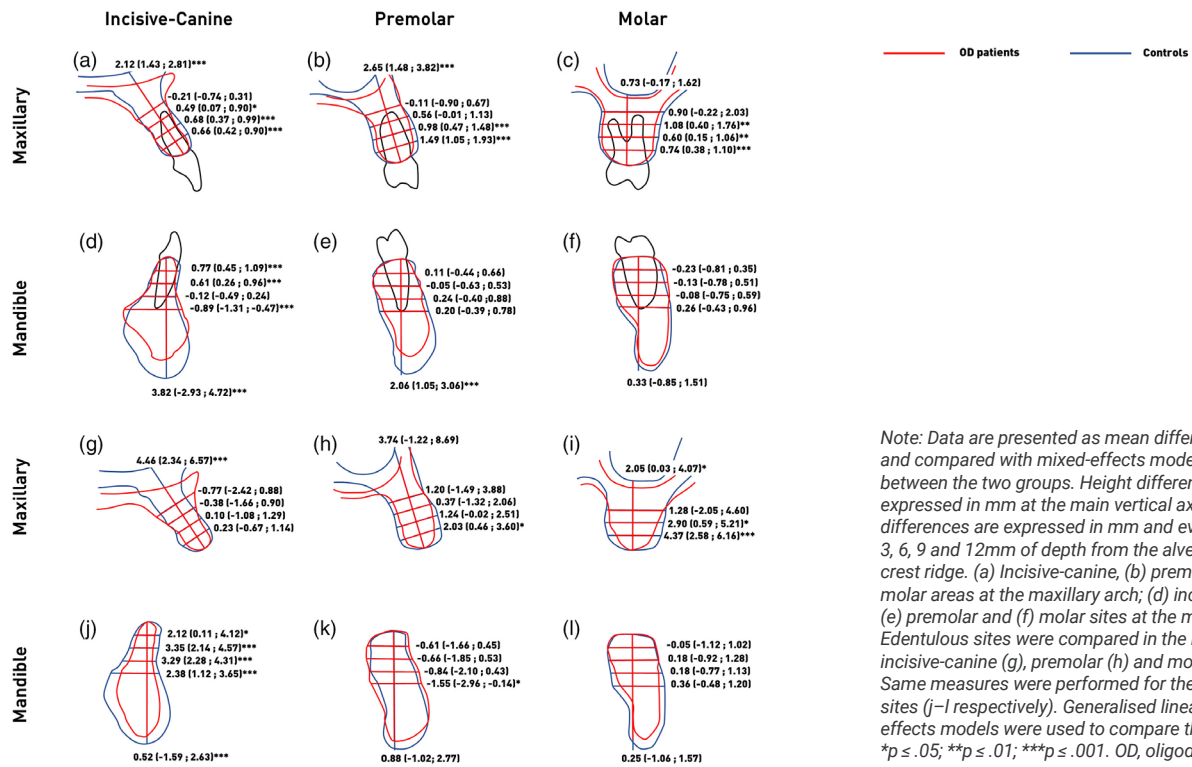
Aim

The primary aim of this study is to evaluate the alveolar-bone dimensions in OD patients in comparison with the control group. The secondary aim is to determine whether retaining deciduous teeth can reduce the effect of bone resorption, and if the lack of posterior teeth affect the position of the inferior alveolar nerve (IAN).

Materials & methods

- This retrospective study consists of a study group of patients with OD (excluding the absence of third molars) and a control group of non-OD patients presenting at least one missing tooth, extracted because of endodontic complications.
- All patients were documented by CBCT imaging three months after tooth extraction to demonstrate complete healing of the socket.
- A total of 53 OD patients (960 sites), divided into 40 lacking mandibular teeth and 32 lacking maxillary teeth. The control group included 82 patients (1,121 sites) divided into 31 lacking mandibular teeth and 51 lacking maxillary teeth. These numbers are after selection based on parameters such as teeth sites, age, and sex.
- Bone measurements were taken by two calibrated examiners of:
 - the distance of the IAN from the crest.
 - the anterior-posterior position of the mental foramens.
- The alveolar-bone height measured on the main vertical axis of tooth or the alveolar-bone crest. The bone width was assessed at 3mm intervals from 3 to 12mm from the crest ridge.
- Demographics, clinical characteristics, the severity of deciduous teeth resorption (graded from 0-2), and the presence of hypohidrotic ectodermal dysplasia were collected and analysed.

Figure: Bone height and width differences between the control group and the oligodontia group



Note: Data are presented as mean differences and compared with mixed-effects model analyses between the two groups. Height differences are expressed in mm at the main vertical axis and width differences are expressed in mm and evaluated at 3, 6, 9 and 12mm of depth from the alveolar bone crest ridge. (a) Incisive-canine, (b) premolar and (c) molar areas at the maxillary arch; (d) incisive-canine, (e) premolar and (f) molar sites at the mandible. Edentulous sites were compared in the maxillary incisive-canine (g), premolar (h) and molar (i) areas. Same measures were performed for the mandible sites (j-l respectively). Generalised linear mixed-effects models were used to compare the groups. * $p \leq .05$; ** $p \leq .01$; *** $p \leq .001$. OD, oligodontia.

Results

- Dimensional assessments between OD patients and control patients showed a significant decrease in alveolar bone height in OD patients, both in edentulous areas and in tooth sites.
- Bone width in the maxilla was thinner in every area in OD patients, while in the mandible only in the anterior region. Bone height was higher in the premolar and molar areas.
- In the mandible, bone height did not differ between the study groups. However, the bone width at the anterior region in OD patients was reduced.
- The presence of deciduous teeth in the incisor-canine region (in both jaws) showed a crest width 2mm wider than in edentulous areas.
- Higher ($p < .001$) and wider bone at every level in male patients compared to female patients.
- Higher bone was associated with OD patients missing six to 11 teeth compared with ones missing 12-25 teeth ($p < .001$).
- Isolated OD patients had both higher bone and thinner bone than ones with hypohidrotic ectodermal dysplasia ($p < .001$).
- Deciduous teeth present showed higher bone height and width at 3mm level than edentulous sites ($p < .001$), but less bone width at 9 and 12mm level ($P < .05$).
- Permanent teeth regions showed higher bone width at every level. No difference was found in bone height.
- In OD patients, when molars were absent, the IAN was 2.41mm ($p = .042$) nearer to the bone crest at the second molar site and 3.46mm ($p = .008$) closer at the first molar site.

Limitations

- The analysis is lacking clinical data – for example, clinical attachment level and gingival phenotype – and this can potentially influence the results.
- No information following the medical health of the control group. This also influences the findings, since other factors may have contributed to the observed differences between the control and the test groups.
- The bone dimension as seen in isolated oligodontia was different from those with a syndrome. This discrepancy may shift the results, as agenesis as part of a syndrome is more prevalent.
- The low number of first and second molar agenesis prevented the authors from understanding the reason for the decreased distance from the IAN. Anatomical variation can also contribute.
- There are no CBCTs with deciduous teeth in the control group.

Conclusions & impact

- CBCT analysis demonstrated that, in comparison to the control group, OD patients show a significant reduction of bone dimensions in both jaws, either in permanent teeth or in edentulous sites.
- In the OD patients, the presence of deciduous teeth is correlated with less bone resorption and can lead to a thicker alveolar bone in comparison to patients without deciduous teeth.
- OD can also affect osteogenesis in addition to odontogenesis.
- Deciduous teeth should be preserved as much as possible near the time of implant surgery. In this way, an optimal bone-crest ridge can be attained, which may make future implant placement less complicated.



JCP Digest 120, published in December 2023, is a summary of "Reduced bone dimension in patients affected by oligodontia: A retrospective study on maxillary and mandibular CBCT". *J Clin Periodontol* 50(12), 1590-1600. DOI: <https://doi.org/10.1111/jcpe.13866>



<https://www.onlinelibrary.wiley.com/doi/10.1111/jcpe.13866>



Access through EFP members' page log-in: <http://efp.org/members/jcp.php>

With kind permission from Wiley Online Library. Copyright © 1999-2023 John Wiley & Sons, Inc. All rights reserved.

JCP Digest is published by the European Federation of Periodontology (EFP). EFP office: Cink Coworking, office No. 17, calle Henri Dunant 15-17, 28036 Madrid, Spain. www.efp.org